

# Pet Doctors Veterinary Supplies and Services

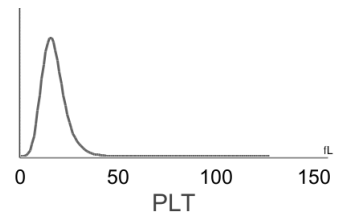
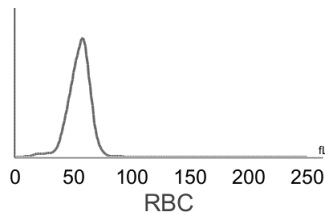
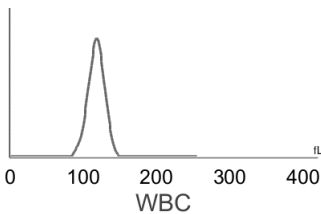
## Blood Morphology Analysis Report

Pet Name: Marshmallow  
 Gender: Female  
 Sample ID: 260515001

Owner Name: Susana May Ramos  
 Age: 7Y  
 Sample Type: Blood

Species: Canine  
 Patient or Visit NO.:  
 Time Tested: 15/05/2026 09:17:57

Test	Result	Unit	Reference Range	Low	Normal	High
<b>1.WBC</b>						
1-1WBC	12.90	10 <sup>9</sup> /L	6.00-17.00			
1-2Neu#	9.14	10 <sup>9</sup> /L	3.62-12.30			
1-3Nst#	0.02	10 <sup>9</sup> /L	0.00-1.00			
1-4Nsg#	9.12	10 <sup>9</sup> /L	2.30-11.50			
1-5Nsh#	0.00	10 <sup>9</sup> /L	0.00-3.50			
1-6Lym#	1.55	10 <sup>9</sup> /L	0.83-4.91			
1-7Mon#	1.14	10 <sup>9</sup> /L	0.14-1.97			
1-8Eos#	1.03	10 <sup>9</sup> /L	0.04-1.62			
1-9Bas#	0.04	10 <sup>9</sup> /L	0.00-0.12			
1-10Neu%	70.9	%	50.0-81.0			
1-11Nst/WBC%	0.2	%	0.0-10.0			
1-12Nsg%	70.7	↑ %	48.0-70.0			
1-13Nsh/WBC%	0.0	%	0.0-15.5			
1-14Lym%	12.0	%	12.0-33.0			
1-15Mon%	8.8	%	2.0-13.0			
1-16Eos%	8.0	%	0.5-10.0			
1-17Bas%	0.3	%	0.0-1.3			
1-18Nst/Neu%	0.2	%	0.0-22.0			
1-19Nsh/Neu%	0.0	%	0.0-20.0			
<b>2.RBC</b>						
2-1RBC	10.98	↑ 10 <sup>12</sup> /L	5.10-8.50			
2-2HGB	231	↑ g/L	110-190			
2-3HCT	68.7	↑ %	35.0-58.0			
2-4MCV	62.5	fL	55.0-83.0			
2-5MCH	21.1	pg	18.0-31.0			
2-6MCHC	339	g/L	260-430			
2-7RDW-CV	18.3	%	11.2-21.3			
2-8RDW-SD	43.1	fL	31.2-51.7			
2-9RET#	5.78	10 <sup>9</sup> /L	3.00-45.00			
2-10RET%	0.05	%	0.00-1.00			
2-11MCVr	47.5	fL	30.0-120.0			
2-12MCVr-CV	45.0	%	20.0-80.0			
2-13NRBC#	0.00	10 <sup>9</sup> /L	0.00-0.10			
2-14NRBC/WBC%	0.00	%	0.00-0.50			
2-15ETG#	0.00	10 <sup>12</sup> /L	0.00-0.10			
2-16ETG%	0.03	%	0.00-3.00			
2-17SPH#	34.99	10 <sup>9</sup> /L	0.00-150.00			
2-18SPH%	0.32	%	0.00-2.00			
2-19AGG#	0.09	10 <sup>9</sup> /L	0.00-0.50			
<b>3.PLT</b>						
3-1PLT	552	↑ 10 <sup>9</sup> /L	117-490			
3-2MPV	9.7	fL	8.4-14.1			
3-3PCT	0.535	%	0.090-0.580			
3-4PDW-CV	64.5	%	30.0-80.0			
3-5PDW-SD	10.6	fL	5.0-20.0			
3-6LPLT#	142	10 <sup>9</sup> /L	0-285			
3-7P-LCR	25.7	%	9.0-50.0			



**Hospital Tel: +639171533903**  
**Hospital Add: McArthur Highway, San Miguel, Calasiao, Pangasinan**



# Pet Doctors Veterinary Supplies and Services

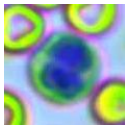

## Blood Morphology Analysis Report

Pet Name: Marshmallow  
 Gender: Female  
 Sample ID: 260515001

Owner Name: Susana May Ramos  
 Age: 7Y  
 Sample Type: Blood

Species: Canine  
 Patient or Visit NO.:  
 Time Tested: 15/05/2026 09:17:57

### Distribution Chart

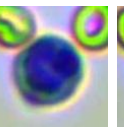
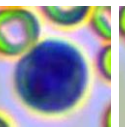

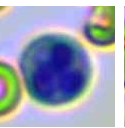
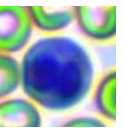
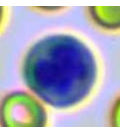
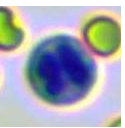
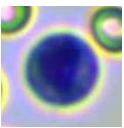
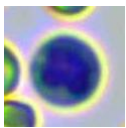


Neutrophil stab granulocytes

Count: 1.0

Concentration:  $0.02 \times 10^9/L$

Percentage: 0.2 Nst#/WBC

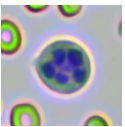


Neutrophil segmented granulocytes

Count: 481.0

Concentration:  $9.12 \times 10^9/L$

Percentage: 70.7 Nsg#/WBC

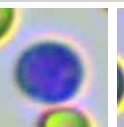
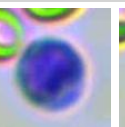



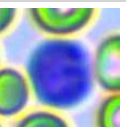


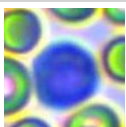



Hypersegmented neutrophils

Count:

Concentration:

Percentage:



Lymphocytes

Count: 79.0

Concentration:  $1.55 \times 10^9/L$

Percentage: 12.0 Lym#/WBC



Hospital Tel: +639171533903

Hospital Add: McArthur Highway, San Miguel, Calasiao, Pangasinan





PLT

**Elevated levels:** Most of them are physiological or secondary, rarely seen in primary. The former is commonly seen in tumors, gastrointestinal diseases such as pancreatitis, hepatitis, inflammatory bowel disease (IBD), colitis, immune-mediated diseases, blood loss/bleeding from various causes, fractures, use of glucocorticoids or antineoplastic drugs, dogs after splenectomy, exercise or injection of epinephrine, etc.; the latter is rarely seen in myeloproliferative diseases.

---

Veterinary Technician: not specified  
Attending Veterinarian: Dr. Mikaela Rabino

Date Reported: 15/05/2026

**This report is solely for the received sample and serves as a diagnostic reference for veterinarians.**



**Hospital Tel: +639171533903**

**Hospital Add: McArthur Highway, San Miguel, Calasiao, Pangasinan**

